

An RCT on treatment of palatally displaced canines with RME and/or a transpalatal arch

Tiziano Baccetti*, Lauren M. Sigler** and James A. McNamara Jr**

*Department of Orthodontics, The University of Florence, Italy and **Department of Orthodontics and Dentofacial Orthopedics, The University of Michigan, Ann Arbor, USA

Correspondence to: Dr Tiziano Baccetti, Via E. Pistelli, 11, 50135 Firenze, Italy. E-mail: tbaccetti@unifi.it

SUMMARY

Aim: To investigate the effect of rapid maxillary expansion (RME) and/or transpalatal arch (TPA) therapy in combination with deciduous canine extraction on the eruption of palatally displaced canines (PDCs). **Subjects and Methods:** Hundred and twenty subjects were enrolled in an RCT based on PDCs diagnosed on panoramic radiographs and they were randomly assigned to one of four study groups. Three treatment groups (TGs) (RME followed by TPA therapy plus extraction of deciduous canines, RME/TPA/EC group, 40 subjects; TPA therapy plus extraction of deciduous canines, TPA/EC group, 25 subjects; extraction of deciduous canines, EC group, 25 subjects) were analyzed. A control group (CG, 30 subjects) received no orthodontic treatment. Prevalence rates of eruption of PDCs in the three TGs were compared with the CG at T2. Predictive features at T1 for successful canine eruption were tested in the three TGs. **Results and Discussion:** The prevalence of canine eruption was 80 per cent for the RME/TPA/EC group, 79 per cent for the TPA/EC group, 62.5 per cent for the EC group, versus 28 per cent in the CG, with statistically significant differences between all the groups, with the exception of the comparison between RME/TPA/EC and TPA/EC. Predictive pretreatment variables for the success of treatment were less severe sectors of canine displacement, prepubertal stages of skeletal maturity, and an open root apex of PDCs. **Conclusions:** The use of a TPA in absence of RME can be equally effective than the RME/TPA combination in PDC cases not requiring maxillary expansion, thus reducing the burden of treatment for the patient.

Introduction

Palatal canine displacement is a genetic disorder that is a precursor to palatal canine impaction, a dental anomaly that afflicts 0.2–2.3 per cent of orthodontic populations (Peck *et al.*, 1994). Treatment for palatal canine impaction involves surgical exposure and guiding mechanics that bring the canine into normal occlusion (Kohavi *et al.*, 1984). Patients with palatally displaced canines (PDCs) must be identified and treated promptly upon diagnosis to reduce the likelihood of impaction (Baccetti *et al.*, 2008a). Prevention of palatal impaction is of significant importance because canine impaction lengthens orthodontic treatment time, complicates orthodontic mechanics, and increases treatment costs (Zuccati *et al.*, 2006; Barlow *et al.*, 2009). Furthermore, canine impaction can have deleterious consequences for adjacent teeth, causing root resorption and/or cyst formation (Becker and Chaushu, 2005).

The most commonly used treatment for the prevention of palatal canine impaction is the extraction of the deciduous canine. Clinical trials performed by Ericson and Kuroi (1988) reported an improvement in the eruption path of 78 per cent of PDCs following extraction of the deciduous canine, while Power and Short (1993) have reported a 62 per cent successful eruption rate with the same interceptive technique. Both these clinical studies lacked the evaluation of an untreated control group (CG). Another prospective

longitudinal study conducted by Baccetti *et al.* (2008a) with the inclusion of an untreated CG indicated that 65 per cent of PDC cases that underwent the extraction of the deciduous canine resulted in successful eruption of permanent canines without any other treatment. The prevalence rate of canine eruption can be improved significantly (up to 88 per cent) by adding forces that prevent mesial migration of the upper posterior teeth after extraction of the deciduous canine, such as those exerted by cervical-pull headgear (Baccetti *et al.* (2008a).

Recent data suggest rapid maxillary expansion (RME) to be a valid interceptive treatment option in PDC patients. A randomized clinical trial (Baccetti *et al.*, 2009) reported that RME therapy in the early mixed dentition successfully encouraged spontaneous eruption in 66 per cent of PDC patients, which only occurred in 14 per cent in an untreated CG of similarly affected individuals. This study used postero-anterior (PA) radiographs to measure the distance of the palatally displaced canine cusp to the face midline to diagnose the presence of PDC. Although maxillary expansion has been proposed as an alternative interceptive treatment for impacted canines (McConnell *et al.*, 1996; Schindel and Duffy, 2007), palatally displaced canines are not correlated to narrow maxillary arches (Langberg and Peck, 2000), and RME therapy is performed in PDC patients with the primary aim of relieving mild to moderate crowding.

The current randomized clinical study was intended to evaluate further the impact of interceptive treatment in subjects presenting with PDCs in the late mixed dentition, which has been indicated as an appropriate time to improve arch perimeter by maxillary expansion (McNamara *et al.*, 2003). The aim of the present prospective controlled study was therefore to assess the prevalence rate of successful eruption of PDCs as diagnosed in the late mixed dentition by means of panoramic radiographs and subsequent treatment with RME, transpalatal arch (TPA), and deciduous canine extraction versus PDCs treated with the use of a TPA and deciduous canine extraction only. An additional aim of this study was to identify pre-treatment predictors of successful outcomes of interceptive treatment of PDCs.

Subjects and methods

The treated and CGs consisted of patients included in a randomized prospective longitudinal clinical trial designed at the Department of Orthodontics of the University of Florence, Italy. It is standard practice that orthodontic patients in the University clinic are given a serial number as they enroll for orthodontic treatment or monitoring. The design of the present study started with patient #4500 through patient #8500 (1991–2009). Criteria for enrollment of subjects in the clinical trial units were as follows:

- Caucasian race;
- age range from 9.5 to 13.0 years at the start of treatment;
- late mixed dentition stage;
- diagnosis of intraosseous malposition of the upper permanent canine(s) derived from the analysis of panoramic radiographs according to the method by Ericson and Kurol (1987) by means of alpha angle, *d* distance, and sector measurements. PDCs showing an alpha angle greater than or equal to 15 degrees were included in the trial (milder forms of PDC were not enrolled). Palatal displacement of the canine(s) was confirmed by evaluating the position of the canine on the lateral cephalogram, and, when necessary, by means of Clark's tube shift rule using multiple intraoral radiographs of the canine region (Bishara *et al.*, 1976). Such PDCs either were unilateral or bilateral.
- stage of skeletal growth ranging from CS 1 to CS 4 as assessed on lateral cephalograms of the examined subjects according to the cervical vertebral maturation method (Baccetti *et al.*, 2005);
- presence of Class II or Class III tendency or mild tooth-size/arch-size discrepancy;
- absence of previous orthodontic treatment; and
- absence of supernumerary teeth, odontomas, cysts, craniofacial malformations, or sequelae of traumatic injuries.

A total of 120 subjects in the late mixed dentition stage with either unilateral or bilateral palatally displaced canines

(3 per cent of the total orthodontic population during the study period) were enrolled in the beginning of the trial (T1). The subjects were allocated to four groups: three treatment groups (TGs; RME followed by TPA therapy plus extraction of deciduous canines, RME/TPA/EC group, 40 subjects, 25 females and 15 males; TPA therapy plus extraction of deciduous canines, TPA/EC group, 25 subjects, 15 females and 10 males; extraction of deciduous canines, EC group, 25 subjects, 14 females and 11 males); CG (30 cases, 18 females and 12 males). Ethical approval was obtained for the enrollment of the subjects in the clinical trial. Informed consent was also signed by the parents of all subjects enrolled in the trial.

Treatment protocols

In the RME/TPA/EC group, the 40 late mixed dentition subjects enrolled for treatment underwent RME. They were treated with a bonded acrylic splint RME that covered the maxillary deciduous first and second molars and maxillary permanent first molars. The midline expansion screw was attached to the appliance with a heavy (0.045 inch) wire framework and routinely was expanded a activated a quarter turn per day until an expansion of about 7 mm was achieved (duration of active expansion was about 1.5 months). After expansion, the RME appliance remained in place for an additional 4–5 months to allow for the reorganization of the disrupted sutural tissue. Following removal of the RME, a TPA was placed on the maxillary first molars and activated according to the protocol described by McNamara and Brudon (2001). TPA treatment is postulated to prevent the mesial movement of maxillary first molars during the transition to the permanent dentition (McNamara *et al.*, 2003). During the TPA treatment, retained maxillary deciduous canines corresponding to the PDCs were extracted. A primary goal for maxillary expansion was to improve the intraosseous position of PDCs (Baccetti *et al.*, 2009). The TPA/EC group received just the TPA in combination with extraction of the deciduous canine/s corresponding to the PDCs, while subjects in the EC group received only the deciduous canine extraction. The CG did not receive any orthodontic treatment.

Diagnostic measurements at T1

Panoramic radiographs of all subjects at T1 were analyzed. The following measurements proposed by Ericson and Kurol (1987) were performed on panoramic radiographs (Figure 1):

- α angle: mesial inclination of the crown of the permanent canine to the midline;
- *d* distance: distance of the cusp tip of the permanent canine from the occlusal line;
- sector: indicating the mesial position of the crown of the displaced canine with respect to the central and lateral incisors (5 sectors, with sector 1 indicating the

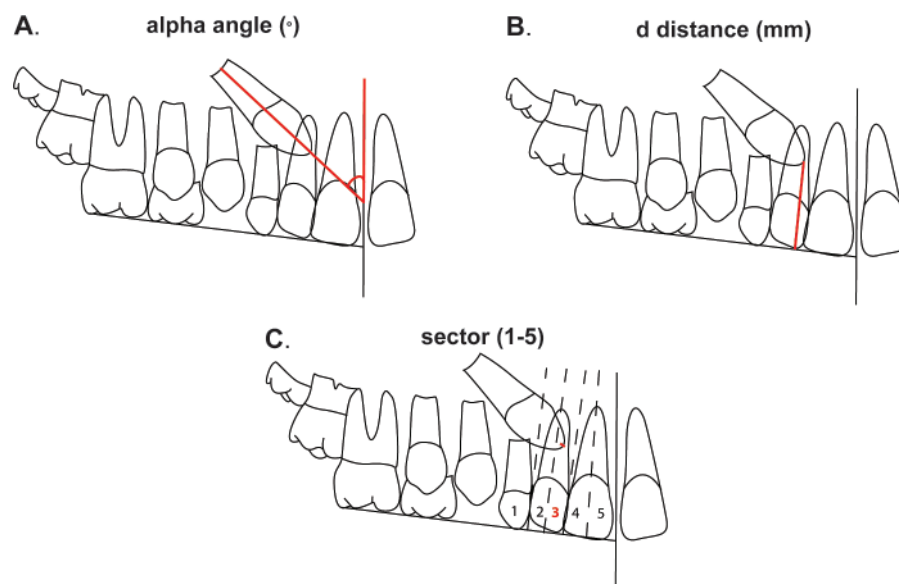


Figure 1 Measurements on panoramic radiographs: (A) alpha angle; (B) *d* distance; (C) sector of displacement (5 areas).

position of the crown of the displaced canine posterior to the distal aspect of the lateral incisor and sector 5 in correspondence with the mesial half of the upper central incisor).

These measurements are valid diagnostic variables for PDC within the age range studied in this trial (Ericson and Kurol, 1987).

The cervical vertebral maturation stage (Baccetti *et al.*, 2005) was evaluated on the lateral cephalograms of all subjects at T1. The development of the root of each PDC was appraised according to the method developed by Nolla (1960).

Re-evaluation at T2

According to the prospective design of the trial, all cases were re-evaluated at a second observation time point (T2) when all subjects would present with an early permanent dentition and a post-pubertal stage of cervical vertebral maturation (CS 5 or CS 6). At T2, unerupted canines were considered impacted because upper permanent canines will not erupt spontaneously after CS 5 (Baccetti *et al.*, 2008b).

The number of enrollment dropouts was recorded. The main outcome investigated at T2 was 'successful' or 'unsuccessful eruption' of the maxillary permanent canines. A 'successful outcome' for PDC was defined as the full eruption of the canine, thus permitting bracket positioning for final arch alignment when needed (Leonardi *et al.*, 2004). An 'unsuccessful outcome' was evident when there was a lack of eruption of the permanent canine (impaction) at the completion of the clinical observation period (T2).

The magnification factor for the panoramic films in both groups was 18 per cent. All measurements were performed, with the investigator blinded as to the group investigated.

Power of the study and method error

The estimate of the power of the study was performed before the beginning of the clinical part of the trial. Taking into consideration the standard deviations of the diagnostic measures on the panoramic radiographs and the use of non-parametric or categorical statistics, the calculated power of the study exceeded 0.90 at an $\alpha = 0.05$ with sample sizes of the examined groups ranging from 25 subjects to 40 subjects.

Accuracy of measurements on panoramic radiographs and dental casts was calculated using the Dahlberg's formula (Dahlberg, 1940) on measures repeated on 15 subjects selected randomly from the two groups. The method error was 1.3 degrees for α angle, 0.7 mm for the *d* distance, and less than 0.2 mm for the 2 dental cast measures. The appraisal of the sector of canine displacement showed a reproducibility of 100 per cent.

Statistical analysis

The starting forms at T1 for measurements on panoramic films and for dental cast measurements were compared in the TG versus the CG with Kruskal–Wallis test and Dunn's *post hoc* tests ($P < 0.05$). The rate of development of the root of displaced canines was compared in the four groups at T1 as well. The prevalence rates for sectors of canine displacement and for the stages in CVM in the four groups at T1 were compared by means of chi-squared tests ($P < 0.05$).

The prevalence rates for successful and unsuccessful cases at T2 in the four groups were compared by means of chi-squared tests ($P < 0.05$). The successful and unsuccessful subjects as defined at the T2 re-evaluation time point in a comprehensive 'TG' that included all treated subjects ($n = 88$ subjects) were compared as to the following variables at T1: alpha angle, d distance, sector, age, cervical vertebral maturation stage, and rate of bilateral PDCs. The rate of development of the root of displaced canines at T1 was compared in successful versus unsuccessful cases. These comparisons were carried out with Mann–Whitney U tests ($P < 0.05$) for metric measures and with chi-squared tests ($P < 0.05$) for categorical measures.

Results

The number of enrollment dropouts from T1 to T2 was one subject in each of the TPA/EC, EC, and CGs (total of 3 dropouts). Dropouts were due to subjects relocating with their families during the T1–T2 observation period. The final sample (Table 1) was comprised 40 subjects (with 66 PDCs) in the RME/TPA/EC group, 24 subjects (with

36 PDCs) in the TPA/EC group, 24 subjects (with 34 PDCs) in the EC group, and 29 subjects (with 42 PDCs) in the CG. The few dropouts did not affect the power of the study. Mean age at T1 for the four groups is reported in Table 1. There were no statistically significant differences among the four groups as to age or gender distribution.

The descriptive statistics for the measurements on dental casts and panoramic films at T1 in the four groups is reported in Table 2. The comparison between the TGs and the CG as to alpha angle, d distance, sector of canine displacement, CVM stage, and unilateral versus bilateral occurrence of PDC did not show any significant difference at T1. Root development of PDCs was similar in the four groups at T1 as well.

The prevalence rate of successful eruption of the maxillary canines was 80 per cent for the RME/TPA/EC group (32/40 subjects), 79.2 per cent for the TPA/EC group (19/24 subjects), 62.5 per cent for the EC group (15/24 subjects), and 27.6 per cent in the CG (8/29 subjects), with statistically significant differences between all the groups, with the exception of the comparison between RME/TPA/EC and TPA/EC.

Table 1 Demographic data for the treated and untreated groups at T1 (y, years and m, months).

	RME/TPA/EC, $n = 40$	TPA/EC, $n = 24$	EC, $n = 24$	CG, $n = 29$	Statistical comparison
Age at T1	10y5m \pm 10m	10y9m \pm 11m	11y1m \pm 11m	10y5m \pm 10m	NS
Age at T2	14y0m \pm 15m	13y7m \pm 10m	13y1m \pm 9m	13y6m \pm 10m	NS
T2–T1 interval	3y6m \pm 16m	2y9m \pm 13m	2y2m \pm 10m	3y1m \pm 14m	NS
Male/female ratio	15/25	10/14	10/14	11/18	NS

NS, not significant.

Table 2 Radiographic data comparisons for the treatment and CGs at T1.

	RME/TPA/EC group, $n = 40$	TPA/EC group, $n = 24$	EC group, $n = 24$	Control group, $n = 29$	Statistical comparisons
Radiographic measures					K-W with Dunn's tests
Alpha angle (degrees)	29.5 \pm 7.9	7.9	28.5	11.0	NS
d distance (mm)	16.9 \pm 2.9	2.8	17.5	3.9	NS
					Chi-squared tests
Sector 1 (%)	15.4	16.6	16.6	27.6	
Sector 2 (%)	51.3	41.6	33.3	48.3	NS
Sector 3 (%)	25.6	33.4	41.6	10.3	
Sector 4 (%)	7.7	8.3	8.7	13.8	
CS 1 (%)	35.9	16.6	33.3	24.1	NS
CS 2 (%)	38.5	50.0	41.6	41.4	
CS 3 (%)	20.5	33.4	16.6	34.5	
CS 4 (%)	5.1	0.0	8.3	0.0	
Unilateral (%)	30.8	41.6	33.3	34.5	NS
Bilateral (%)	69.2	58.4	66.7	65.5	
	Median	Median	Median	Range	K-W with Dunn's tests
Root development of PDC (range)	8.75 (7.25–9.50)	8.25 (7.00–9.50)	8.50 (7.50–9.50)	8.75 (7.50–9.50)	NS

NS, not significant.

		Unsuccessful, <i>n</i> = 21 (RME/TPA/EC = 8; TPA/EC = 5; EC = 8)			Successful, <i>n</i> = 67 (RME/TPA/EC = 32; TPA/EC = 19; EC = 16)			
Radiographic measures		Mean	SD		Mean	SD	Mean Difference	Mann-Whitney test
Alpha angle T1 (degrees)		33.9	7.0		24.6	6.9	-9.3	***
<i>d</i> distance T1 (mm)		17.0	3.8		16.5	3.1	-0.5	NS
		Number of cases	Percentage		Number of cases	Percentage		Chi-squared test
Sector 1		1	4.7		13	17.9	'Mild/moderate' = 68.7%	***
Sector 2		5	23.8		34	50.8		
Sector 3		10	47.9		18	26.8	'Severe' = 31.3%	
Sector 4		5	23.8		2	2.3		
CS 1		3	14.2		23	34.3	'Pre-pubertal' = 82.0%	
CS 2		5	23.8		32	47.7		***
CS 3		9	44.4		11	18.0	'Pubertal' = 18.0%	
CS 4		4	17.6		0	0.0		
Unilateral		8	35.2		22	32.9		NS
Bilateral		13	64.8		45	67.1		
Root development of PDC		Median	Range		Median	Range	% PDC stage 9 or >9	Mann-Whitney test
		9.00	8.00-9.75		8.00	7.00-9.25	10.0	***

The comparison between successful versus unsuccessful subjects in the three TGs combined together (TG group, Table 3) revealed that, while there was no statistically significant difference for *d* distance, the alpha angle was significantly smaller in successful cases. Also, the prevalence rate for less severe sectors of canine displacement (sectors 1 and 2) was significantly greater in successfully treated cases than in unsuccessful ones. The prevalence rate at T1 for pubertal stages of CVM (CS 3 or CS 4, 62 per cent) was significantly greater in unsuccessful treated cases than in successful treated cases, in which 82 per cent presented in a pre-pubertal stage at the beginning of interceptive orthodontic treatment. The unsuccessful cases in treated groups presented with a significantly more advanced development of the root of displaced canine/s than successful cases. The percentage of cases with a root development stage 9 or >9 according to Nolla (closed root apex; Nolla, 1960) was five times greater in unsuccessful treated subjects than in successful treated subjects (Table 3). No differences were found regarding bilateral versus unilateral occurrence of PDC with regard to canine eruption (Table 3).

Discussion

In the RME/TPA/EC patients, the RME protocol was carried out with the main objective of improving the eruption process of PDCs within other orthodontic indications (e.g., mild to moderate crowding of the dental arches, tendency toward Class II or Class III malocclusion). RME followed by a TPA in conjunction with extraction of the deciduous canines in late mixed dentition patients was significantly more effective at inducing successful eruption of PDCs (80 per cent) than no treatment (28 per cent), or extraction of the deciduous canine/s only (62.5 per cent). These results can be contrasted with those from a recent randomized clinical trial that found RME to increase the rate of successful canine eruption in early mixed dentition PDC patients (65 per cent) when compared to an untreated CG (14 per cent; [Baccetti *et al.*, 2009](#)). However, in this previous study diagnosis of PDC had been carried out on PA

radiographs before the age of 9 years, and the TPA was not used to prevent mesial migration of maxillary posterior teeth. Also the use of a TPA in conjunction with extraction of the deciduous canines in late mixed dentition patients, in absence of previous use of an RME, was significantly more effective at inducing successful eruption of PDCs (79.2 per cent) than no treatment or extraction of the deciduous canine/s only (62.5 per cent).

When comparing the prevalence rate for successful PDC eruption between RME interceptive treatment in this study with previous studies that used other interceptive treatment modalities, both the RME/TPA and the TPA groups presented with a slightly higher rate of effectiveness (about 80 per cent) than what has been reported for extraction of the deciduous canine alone (78 per cent according to [Ericson and Kurol \(1988\)](#) and 62 per cent according to [Power and Short \(1993\)](#)). It should be noted, however, that the prevalence rate for favorable outcomes in the study by [Ericson and Kurol \(1988\)](#) included both canine eruption and improvement of canine eruption path, while in the present clinical trial, only full eruption of the canines was considered. Also, the prevalence rates reported in both the studies ([Ericson and Kurol, 1987](#); [Power and Short, 1993](#)) refer to individual PDCs, while the prevalence rates for success/failure in the current study refer to 'subjects' who may present with unilateral or bilateral PDCs. As palatal displacement of upper canines has been shown to have a fundamental component of genetic origin ([Peck et al., 1994](#); [Leonardi et al., 2004](#)), the use of single canines as statistical units is not recommended since general etiologic factors may affect the eruption process of both upper canines within the same subject.

The success rate of RME/TPA or TPA treatment as compared to extraction of the deciduous canine in combination with fixed appliance therapy (75 per cent according to [Olive \(2002\)](#)) is similar, whereas the success rate is slightly smaller than the prevalence rate for the eruption of the canines following the use of cervical-pull headgear and extraction of the deciduous canine (88 per cent) as determined by [Baccetti et al. \(2008a\)](#). However, when the prevalence rate for successful eruption of PDCs is compared between treated and CGs within the present study and the study by [Baccetti et al. \(2008a\)](#), the proportion of favorable outcomes in the RME/TPA/EC or the TPA/EC samples over the respective controls (2.8 times more) actually is greater than the proportion found in subjects treated with cervical pull headgear/deciduous canine extraction over the respective controls (2.4 times more).

Possible pre-treatment predictors of a successful outcome of interceptive treatment of PDCs by means of interceptive orthodontic therapy were identified. Interceptive treatment of PDCs in the late mixed dentition was less successful in facilitating canine eruption in patients who began treatment at CS 3 or CS 4 in cervical vertebral maturation (pubertal patients) than in patients who began treatment at CS 1 or

CS 2 (pre-pubertal patients). Sixty-two per cent of patients in the unsuccessful TG were at the pubertal stages in skeletal maturation, and 82 per cent of patients in the successful TG were at a pre-pubertal cervical stage. Moreover, canines that exhibited more severe displacement as revealed by the alpha angle or 'sector' measures were less likely to erupt successfully. Similarly, a recent retrospective study conducted by [Olive \(2005\)](#) found that the more mesial the cusp of the PDC (a measurement analogous to the sector measurement) before treatment, the longer the duration of treatment for impacted canines. These results are also similar to findings by [Baccetti et al. \(2007\)](#), who found the two measurements on panoramic radiographs to be a valuable prognostic indicator for success of combined surgical and orthodontic treatment of impacted canines.

PDCs with a fully developed root demonstrated significantly less probability of successful eruption following interceptive treatment. TGs showed a smaller prevalence of successful eruption of PDCs when the root apex was closed (Nolla's stage 9 or greater; [Nolla, 1960](#)). A higher prevalence rate of eruption was seen for PDCs in which the root apex was still developing (even when more than two-thirds of the root had already formed as in Nolla's stage 8; [Nolla, 1960](#)). These data confirm previous observations by [Kokich and Mathews \(1993\)](#), who reported a high probability of impaction when the root apex of the tooth is complete. When the information derived from the canine root development is combined with the data concerning the CVM staging of observed subjects in the present study, it can be concluded that interceptive treatment for PDCs at a pre-pubertal stage in skeletal maturation and before the closure of the PDC root apex leads to significantly more successful outcomes than postponing treatment until puberty or at a time when the apex of the canine is formed completely.

A general overview of the possibilities offered by various protocols of interceptive treatment for PDCs suggests that the extraction of the deciduous canine alone is able to double the chance of eruption of the palatally displaced upper permanent canine between 10 and 13 years of age (about 60 to 65 per cent eruption) ([Ericson and Kurol, 1988](#); [Power and Short, 1993](#); [Baccetti et al., 2008a](#)). The addition of other therapeutic adjuncts in the late mixed dentition, such as the RME/TPA approach described here or the cervical-pull headgear investigated by [Baccetti et al. \(2008a\)](#) increase the prevalence rate of successful eruption of the canine following interceptive treatment up to 80–90%. However, a greater burden of treatment is placed on the patient when these more complex approaches are used in comparison to the simple extraction of the associated deciduous tooth. In cases showing an indication for either one of the two combination treatment protocols, such as maxillary transverse deficiencies for the RME approach or the need for molar distalization for the headgear approach,

the highly significant facilitation of eruption of PDCs should be considered as an extremely favorable side effect of these orthodontic options in the late mixed dentition. An alternative effective approach that can be recommended in a large variety of clinical conditions associated with PDCs is the use of a TPA in combination with the extraction of the deciduous canines, as this space maintenance protocol is compliance-free, is minimally invasive on the patient, and it leads to a prevalence rate of successful outcomes similar to the more complex treatment protocols that include either RME or headgears.

Conclusions

This RCT found that RME followed by a TPA coupled with extraction of the deciduous canine, as well as TPA and deciduous canine extraction alone, to be *n* effective interceptive treatment options for patients from 9 years 5 months to 13 years of age who present with palatally displaced canines. The use of these protocols in late mixed dentition subjects increases the rate of eruption of PDCs significantly (about 80 per cent for the RME/TPA/EC and TPA/EC groups and 65.2 per cent for the EC group) when compared with an untreated PDC CG (28 per cent).

The following radiographic factors are indicative of prognosis of impaction following interceptive treatment including RME/TPA therapy: pubertal CVM stages versus pre-pubertal, more mesial sectors of intraosseous displacement of the canine, greater alpha angles, and closure of the canine root apex.

When the burden of treatment and an effort/benefit analysis of the outcomes of interceptive treatment of PDCs are considered, treatment represented by the use of a TPA in combination with the extraction of the deciduous canine/s in the late mixed dentition appears to be a reasonable and efficient procedure to avoid palatal impaction of maxillary canines.

References

- Baccetti T, Franchi L, McNamara J A Jr 2005 The cervical vertebral maturation (CVM) method for the assessment of optimal treatment timing in dentofacial orthopedics. *Seminars in Orthodontics* 11: 119–129
- Baccetti T, Leonardi M, Armi P 2008a A randomized clinical study of two interceptive approaches to palatally displaced canines. *European Journal of Orthodontics* 30: 381–385
- Baccetti T, Franchi L, De Lisa S, Giuntini V 2008b Eruption of the maxillary canines in relation to skeletal maturity. *American Journal of Orthodontics and Dentofacial Orthopedics* 133: 748–751
- Baccetti T, Mucedero M, Leonardi M, Cozza P 2009 Interceptive treatment of palatal impaction of maxillary canines with rapid maxillary expansion: a randomized clinical trial. *American Journal of Orthodontics and Dentofacial Orthopedics*, 136: 657–661
- Baccetti T, Crescini A, Nieri M, Rotundo R, Pini Prato G P 2007 Orthodontic treatment of impacted maxillary canines: an appraisal of prognostic values. *Progress in Orthodontics* 8: 6–15
- Barlow S T, Moore M B, Sheriff M, Ireland A J, Sandy J R 2009 Palatally impacted canines and the modified index of orthodontic treatment need. *European Journal of Orthodontics* 31: 362–366
- Becker A, Chaushu S 2005 Long-term follow-up of severely resorbed maxillary incisors after resolution of an etiologically associated impacted canine. *American Journal of Orthodontics and Dentofacial Orthopedics* 127: 650–654
- Bishara S E, Kommer D D, McNeil M H, Montagano L N, Oesterle L J, Youngquist W 1976 Management of impacted canines. *American Journal of Orthodontics* 69: 371–387
- Dahlberg A G 1940 Statistical methods for medical and biological students. Bradford and Dickens, London
- Ericson S, Kurol J 1987 Radiographic examination of ectopically erupting maxillary canines. *American Journal of Orthodontics and Dentofacial Orthopedics* 91: 483–492
- Ericson S, Kurol J 1988 Early treatment of palatally erupting maxillary canines by extraction of the primary canines. *European Journal of Orthodontics* 10: 283–295
- Kohavi D, Becker A, Zilberman Y 1984 Surgical exposure, orthodontic movement, and final tooth position as factors in periodontal breakdown of treated palatally impacted canines. *American Journal of Orthodontics* 85: 72–77
- Kokich V G, Mathews D P 1993 Surgical and orthodontic management of impacted teeth. *Dental Clinics North America* 37: 181–204
- Langberg B J, Peck S 2000 Adequacy of maxillary dental arch width in patients with palatally displaced canines. *American Journal of Orthodontics and Dentofacial Orthopedics* 118: 220–223
- Leonardi M, Armi P, Franchi L, Baccetti T 2004 Two interceptive approaches to palatally displaced canines: a prospective longitudinal study. *Angle Orthodontist* 74: 581–586
- McConnell T L, Hoffmann D L, Forbes D P, Janzen E K, Weintraub N H 1996 Maxillary canine impaction in patients with transverse maxillary deficiency. *ASDC Journal of Dentistry for Children* 63: 190–195
- McNamara J A Jr, Brudon W L 2001 Orthodontics and dentofacial orthopedics. Needham Press, Ann Arbor
- McNamara J A Jr, Baccetti T, Franchi L, Herberger T A 2003 Rapid maxillary expansion followed by fixed appliances: A long-term evaluation of changes in arch dimensions. *Angle Orthodontics* 73: 344–353
- Nolla C M 1960 The development of permanent teeth. *Journal of Dentistry of Children* 27: 254–266
- Olive R J 2002 Orthodontic treatment of palatally impacted maxillary canines. *Australian Orthodontic Journal* 18: 64–70
- Olive R J 2005 Factors influencing the non-surgical eruption of palatally impacted canines. *Australian Orthodontic Journal* 21: 95–101
- Peck S, Peck L, Kataja M 1994 The palatally displaced canine as a dental anomaly of genetic origin. *Angle Orthodontist* 64: 249–256
- Power S M, Short M B 1993 An investigation into the response of palatally displaced canines to the removal of primary canines and an assessment of factors contributing to favourable eruption. *British Journal of Orthodontics* 20: 215–223
- Schindel R H, Duffy S L 2007 Maxillary transverse discrepancies and potentially impacted maxillary canines in mixed-dentition patients. *Angle Orthodontist* 77: 430–435
- Zuccati G, Ghobadlu J, Nieri M, Clauser C 2006 Factors associated with the duration of forced eruption of impacted maxillary canines: a retrospective study. *American Journal of Orthodontics and Dentofacial Orthopedics* 130: 349–356